

# The Use of a Calcaneal Reconstruction Plate<sup>1</sup> in Intra-Articular Calcaneal Fractures

Treatment of intra-articular calcaneal fractures has a long and varied history. New techniques and application of computerized tomography technology has greatly improved the prognosis and is summarized here. A case report with the use of a calcaneal reconstruction plate is presented. The authors suggest that in comminuted calcaneal fractures that possess a defect in the cancellous bone of the calcaneal body, this plate will triangulate fixation over the defect and provide for better support of the posterior facet of the subtalar joint. (The Journal of Foot and Ankle Surgery 35(4):318-330, 1996)

Key words: foot, calcaneal fracture; calcaneous, fracture

Jared P. Frankel, DPM, FACFAS<sup>2</sup>  
Charles D. Anderson, DPM<sup>3</sup>

Calcaneal fractures involving the subtalar joint historically have had a poor prognosis. The complex three-dimensional nature and thin cortical shell of the calcaneus have made diagnosis and treatment difficult. The advent and wide use of computerized tomography (CT) scanning and refinement of fixation techniques have now made accurate diagnosis and close anatomic reduction of the calcaneus possible, resulting in better clinical outcomes. A variety of plates are now used for fixation when the calcaneus is comminuted. A case report is presented using a calcaneal reconstruction plate.

## Literature Review of Current Therapy

### Mechanism and Pathological Anatomy

It has not been unanimously agreed upon where the initial fracture line occurs. Palmer stated that the primary fracture is a vertical shear fracture and divides the posterior facet of the calcaneus into medial and lateral components (1). Other authors agree (2-5) (Fig. 1A). Essex-Lopresti stated that the initial fracture is caused by the lateral process of the talus being driven into the

calcaneus (6). The fracture line is vertical and extends from the crucial angle of Gissane<sup>4</sup> to the plantar aspect of the calcaneus. He referred to this as the "outer route" (6) (Fig. 1B). With additional force, Essex-Lopresti stated that the sustentaculum tali and the medial one-third to one-half of the posterior facet is then sheared off medially. He referred to this as the "inner route." Both of these features were found to be "remarkably constant" (6). If the force continues, he states, one of two patterns will then be seen. A tongue-type fracture line (type A) is seen from the crucial angle to the posterior tuberosity and is thought to occur when the foot is in a plantarflexed attitude on impact. A joint-depression-type fracture line (type B) exits behind the posterior subtalar joint and is thought to occur when the foot is in a dorsiflexed attitude (6) (Fig. 1C).

Current thought in joint depression fractures agrees with Palmer in stating that the vertical shearing of the sustentaculum tali is the primary fracture (5, 7-10) and as the force continues, the entire posterior lateral edge of the talus further compresses and comminutes the posterior facet of the subtalar joint and body of the calcaneus (4). This is supported by two studies. Eastwood *et al.* found only five two-part calcaneal fractures out of 120 studied, and these consisted of medial and lateral fragments (11). Letournel also rarely encountered two-part fractures, but when present they were isolated fractures of the sustentaculum not involving the posterior facet (9).

In experimental studies with cadavers, Carr, Hamilton, and Bear (12) produced fractures that showed both kinds of primary fracture lines in 16 of 18 specimens. Of the remaining two specimens, one had a longitudinal

From the Lincoln West Hospital Surgical Residency Program, Chicago, Illinois.

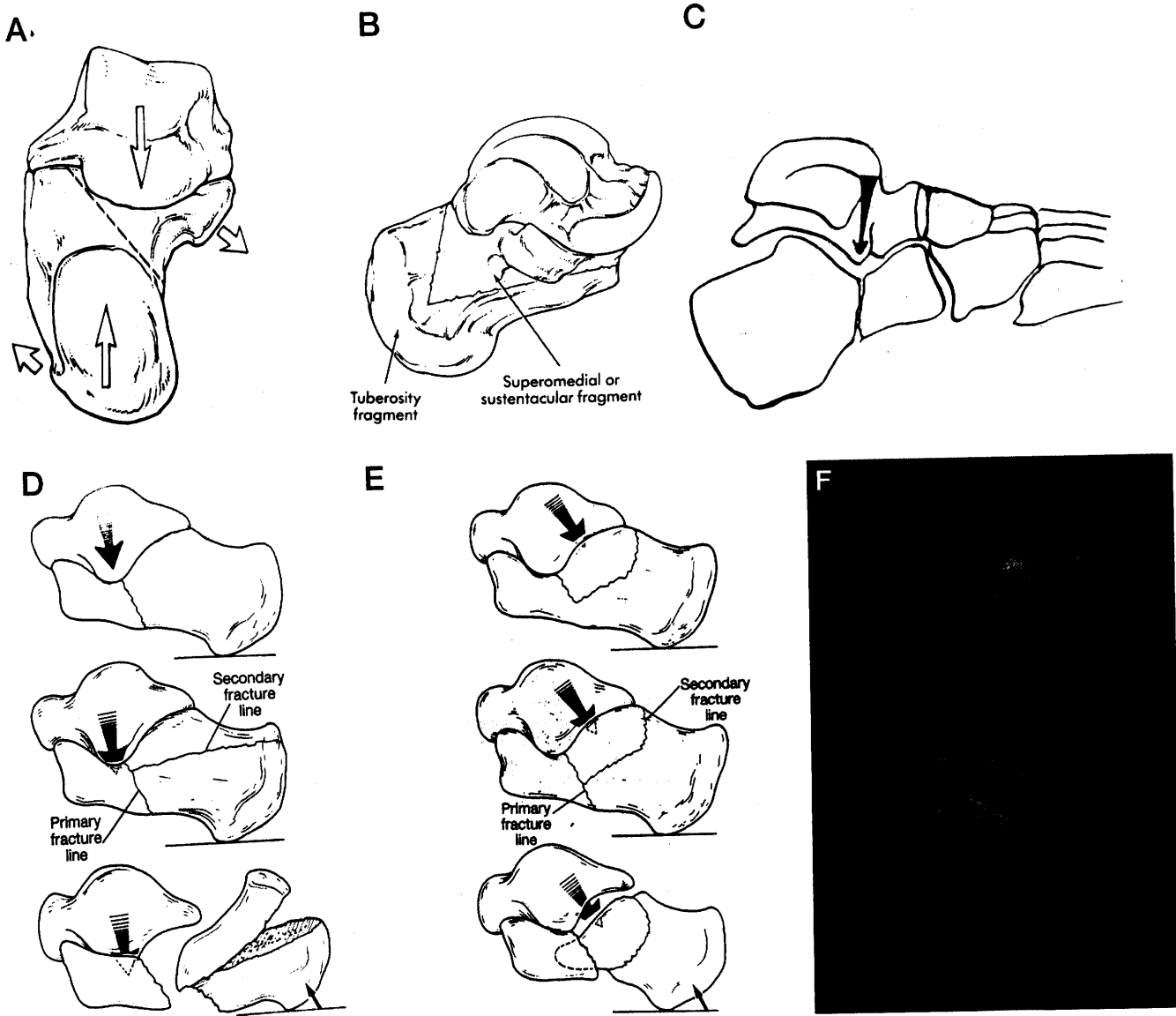
<sup>1</sup> Synthes, Paoli, PA.

<sup>2</sup> Diplomate, American Board of Podiatric Surgery. Residency Director. Address correspondence to: Elmhurst Podiatry Center, 277 N. York Rd., Elmhurst, IL 60126.

<sup>3</sup> Submitted during second year residency.

<sup>4</sup> The crucial angle of Gissane is seen on lateral radiograph and is formed by the subchondral bone of the posterior facet and the lateral-dorsal cortical strut of the anterior process.

The Journal of Foot and Ankle Surgery 1067-2516/96/3504-0318\$3.00/0  
Copyright © 1996 by the American College of Foot and Ankle Surgeons



**FIGURE 1** A, B. Shearing fracture that divides the calcaneus into medial and lateral portions. (Used with permission.) C, Lateral process of talus creating vertical fracture at the angle of Gissane. The calcaneus is divided into anterior and posterior portions. (Used with permission.) D, E, Essex-Lopresti's classifications of intra-articular calcaneal fractures. Tongue-type fracture on the left and joint-depression fracture on the right. F, Transverse plane CT of intra-articular calcaneal fracture with lateral process of the talus marked with a triangle.

primary fracture and the other had a transverse primary fracture. It therefore appears that both fracture mechanisms may actually occur. While great strides have been made in fracture identification and subsequent treatment, it is obvious that the mystery of calcaneal fracture mechanisms is neither fully understood nor predictable. A substantial intra-articular calcaneal fracture has at least four parts, and any of these may be comminuted into many more pieces. Analogies have been made between a calcaneus and an egg (13). Cracking an egg by hand so it cracks the same way each time rarely occurs. While eggs appear to have the same exact shape, many variations occur. These subtle variations in shape, as well

as the position of the egg, and the amount and direction of force used when cracking an egg, contribute to the unpredictability afforded by the combination of variables.

These subtle variations in shape exist in human calcaneal anatomy. An individual's calcaneal anatomy can vary significantly from one person to another. The orientation of the subtalar joint axis and the calcaneal inclination angle probably account in some way as to how the calcaneus fractures. An increased calcaneal inclination angle causes the calcaneus to be dorsiflexed in relation to the ground, and therefore may tend to fracture in a joint-depression pattern. A decreased cal-

canal inclination angle may tend to fracture in a tongue-type fracture pattern. To study this phenomenon, previous x-rays, if available, or the unaffected side in unilateral cases could be used for comparison.

\* The anatomy after the calcaneus has fractured is now well known because of the use of CT scans. The sustentaculum tali always remains aligned with the talus because of the deltoid and interosseus talocalcaneal ligaments (9, 11, 14-17). The fracture line is always lateral to the interosseus ligament (15). This is important because fixation is based on reducing all fragments to this stable and constant sustentacular fragment (4, 15).

The next constant finding is the fracture of the posterior facet in the sagittal plane. The posterior facet may be fractured into as many as three pieces (7). Part of the medial posterior facet may remain with the sustentaculum. A central piece may be depressed below the level of the articular surface. The lateral-most portion of the posterior facet remains attached to the lateral wall (2, 5). The medial fracture line appears to be from the shearing force and the lateral fracture is from the posterolateral edge of the talus (12). This fragment usually has rotated into a valgus position (11) and frequently the lateral fragment is found on the inside of the body of the calcaneus. These lateral fracture fragments usually contain 41% of the articular surface (11).

The lateral wall blow-out is considered the last consistent part of all intra-articular fractures (3, 5). This is a result of the lateral process of the talus pushing the posterior facet into the body, thereby forcing the lateral wall outward (18). The lateral process of the talus is composed of thickened cortical bone and is directly supported by the lateral malleolus. The thinner eggshell-like cortex that composes the floor of the sinus tarsi of the calcaneus can provide little resistance against the pathological force of the lateral process. Once the cortical shell is broken, as with an egg, the strength of the calcaneus is weakened considerably. The lateral process of the talus continues its downward force and further comminutes the calcaneus (Fig. 1D). The sagittal plane fracture created by the lateral process will either exit the lateral wall distally or continue into the calcaneocuboid joint (3, 5). Hutchinson and Huebner found an anterolateral fracture that coursed into the calcaneocuboid joint in 51% of their subjects (19). Eastwood found calcaneocuboid joint fractures in 41% (11). Ruch and Taylor theorized this correlated to the position of the foot and, more specifically, the position of the lateral process of the talus. When the foot is pronated, the fracture will course into the calcaneocuboid joint. When the foot is supinated, the fracture will exit the lateral wall (5). In summary, there are three constant components to most intra-articular fractures: the vertical shearing fracture resulting in the sustentacular fragment, the sagittal

plane fracture of the posterior facet, and the lateral cortical wall fracture exiting laterally or into the calcaneocuboid joint (2, 5, 8).

## Diagnosis

While plain film radiographs are still the initial studies of all foot and ankle trauma, in calcaneal fractures they aid only in making an initial diagnosis. A lateral projection of the foot and ankle may show a change in the crucial angle of Gissane or Bohler's tuber joint angle<sup>5</sup>. Measurements of Bohler's angle may be of limited value. When only the lateral portion of the posterior facet is displaced, a "double density" is seen and Bohler's angle appears normal (20). Restoration of Bohler's angle after surgery does not necessarily correlate with good or excellent clinical results (18). An axial calcaneal view will show the medial spike of the sheared sustentaculum tali fragment. A Broden's view<sup>6</sup> may be used for initial evaluation of the posterior facet of the subtalar joint (21). This view is the most useful of all of the plain films, because of its benefit in assessing the posterior facet during open reduction and internal fixation. A dorsal-plantar projection will show a fracture of the calcaneocuboid joint if it is involved.

A CT scan will reveal the three-dimensional nature of the injury not evident on plain films and aid in evaluating the extent of the injury (2, 5, 8, 14, 16, 19, 22). Therefore, CT scans are a necessity when evaluating calcaneal fractures (14). They provide for the most consistent analysis (20, 21), aid in optimal selection of treatment (2), and also provide for consistent analysis of treatment results (7).

## Classification

Traditional classifications are based on plain film radiographs. The most commonly used are by Rowe and Essex-Lopresti (6, 23). Rowe's type I, II, and III classifications have been used for those fractures that do not involve the subtalar joint, and Essex-Lopresti's classifications have been used for those fractures that do involve the subtalar joint (2, 5). Essex-Lopresti's classification includes a type A (tongue-type) and a type B (joint-depression type), with the most common being the joint-depression type (2, 6, 11, 23) (Fig. 1D, E). Both of these classifications fail to describe all of the anatomy

<sup>5</sup> Bohler's "tuber-joint" angle is seen on a lateral radiograph and is defined as "...between the upper contour of the tuberosity... and the line uniting the highest point of the anterior process with the highest point of the posterior articular surface, an angle of 30 to 35°" (17).

<sup>6</sup> In Broden's view "The patient is placed supine with the x-ray cassette placed under the leg and ankle. The foot is in neutral flexion with the leg internally rotated 30° to 40°. The x-ray beam is then centered over the lateral malleolus and four views are taken with the tube angled 40°, 30°, 20°, and 10°, respectively, toward the head" (20).

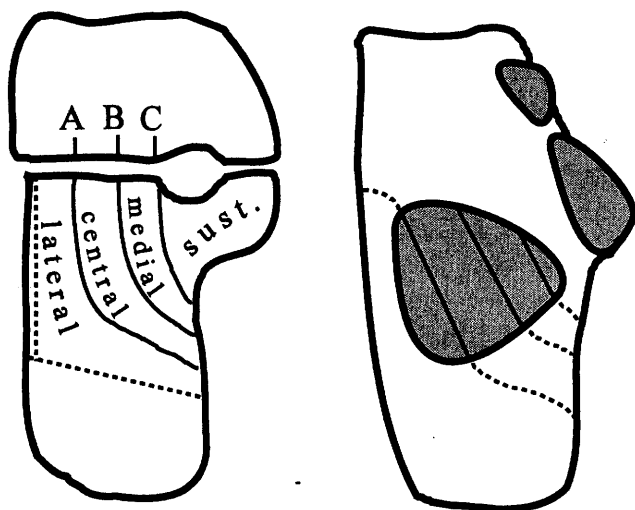
involved in intra-articular calcaneal fractures because they are based on plain film radiographs and are therefore limited in their prognostic ability for treatment.

Newer classifications based on CT scans reveal the three-dimensional nature of the calcaneal fracture. The classification for intra-articular fractures was presented by Soeur and Remy (24) and emphasized the importance of identifying the fragments of the posterior facet for proper treatment of calcaneal fractures. Their classification was applied to CT scans by Sanders (7), and is as follows (Fig. 2). Coronal and transverse CT scans are taken, but the classification is based only on the coronal view. For this view, the patient is positioned with the feet flat on the gantry and a scout film is obtained. The cuts are then made perpendicular to the posterior facet of the subtalar joint in 3-mm. sections (20). A view is chosen so that the posterior facet is the widest and is then divided by three lines: lateral, central, and medial. These lines are labeled A, B, C, with A being lateral and C being medial. It is possible then to have four basic pieces: three joint fragments and the sustentaculum tali. Type I includes all non-displaced articular fractures. Types II, III, and IV directly correspond to the number of joint fragments. Type II fractures are divided into IIA, IIB, and IIC. Type III fractures typically feature a centrally depressed fragment. They are divided into IIIAB, IIIAC, and IIIBC. Type IV fractures contain all of the fracture lines.

The classification is based on the posterior facet because reduction of this facet correlates with clinical outcome (7, 18, 19, 21, 25). The criteria of Sanders *et al.* for reduction of this joint are as follows: an "anatomic" reduction has no articular incongruity whatsoever, a

"near-anatomic" reduction has less than 3 mm. of articular incongruity or gapping between fragments, an "approximate" reduction has 3 to 5 mm. of articular incongruity or gapping between fragments, and a "failure" in reduction has more than 5 mm. of articular incongruity or gapping between fragments (25). Two important concepts that correlated with long-term results were discovered in the study by Sanders *et al.* of 120 displaced intra-articular fractures. First, anatomic reduction of the posterior facet was possible in 86% of type II fractures, 60% of type III fractures, and 0% of type IV fractures. These resulted in excellent or good clinical results in 73% of type II fractures, 70% of type III fractures, and 9% of type IV fractures. In all cases, the height, length, and width of the heel were reduced to 98%, 100%, and 110% (wider) of normal, respectively. Second, a learning curve appeared showing that a surgeon's results of type II and III fractures became fairly predictable after 35 to 50 cases or roughly 2 years. In type IV fractures, even the most experienced surgeon will not get good results, because of the numerous fragments and irreversible damage to the articular cartilage at the time of injury (25).

According to Hutchinson and Huebner, a satisfactory reduction of the posterior facet that correlates with good or excellent clinical outcome is defined as "... no more than 2 mm. of articular step-off, less than 4 mm. of gap of the articular surface." Also included is "... near elimination of lateral extrusion, and no major overlap or malposition of the medial wall" (19). Additional variables studied that did not correlate with the clinical outcome included age, degree of comminution, bilateralism, calcaneocuboid joint involvement, joint-depression *versus* tongue-type fracture, or the final Bohler's angle. An interesting variable that did correlate with clinical outcome was workers' compensation claims. With everything else being equal, 90.5% of patients not injured on the job had a satisfactory result, but only 61.5% had a satisfactory result if filing a workers' compensation claim (19).



**FIGURE 2** Sanders' CT classification based on the coronal view of the posterior facet of the subtalar joint (*left*). Superior surface of a calcaneus with fracture lines drawn on the posterior facet (*right*).

### Treatment

This paper will only address intra-articular fracture treatment. Historically, various treatment methods have been used. Ruch and Taylor summarized this to include "(a) compression bandaging and early mobilization (nonreduction technique), (b) closed manipulation or semi-invasive manipulative techniques with traction spikes or pins, (c) open reduction with various methods of internal fixation, and (d) primary arthrodesis" (5). Whatever the methods used, the goals are the same: to restore the form and function of the calcaneus and restore the form and function of the subtalar joint (and

sometimes the calcaneocuboid joint) (9, 26). Restoration of the form of the calcaneus is the primary goal. Of lesser importance is the restoration of the form and function of the subtalar and calcaneocuboid joint surfaces. Optimally, both can be achieved.

Restoring the form of the calcaneus restores its function, which is to support the weight of the body, provide a lever arm for the plantarflexors of the foot, and dissipate shock. To do this, the calcaneus must sit underneath the talus in the middle of the weightbearing force without varus or excessive valgus. The width must be reduced and the height regained (27). This is of utmost importance, because a patient may function without a subtalar joint, but if the calcaneus is not restored to its original height and width, the patient will not be able to fit into regular shoe gear (7, 21), the fibula may impinge on the shoe counter or the calcaneus itself (13, 28), and plantarflexory power will be lost (17). Also, by restoring the anatomy of the calcaneus, arthrodesis will be easier to perform, if the need arises later (4, 19, 29). Treatment by the nonreduction technique of compression bandaging and early mobilization will fail in this goal.

By restoring the form of the subtalar and sometimes the calcaneocuboid joint, one restores the function, which is to dissipate rotational forces of the lower extremity. Restoration of the form is achieved through precise anatomic reduction of their joint surfaces. A poor anatomical result correlates with an unsatisfactory clinical outcome (18, 19, 22, 25, 30). Treatment by closed manipulation, or semi-invasive manipulation with traction spikes or pins will fail in this goal (14).

Besides precise anatomic reduction of joint surfaces, restoration of the overall anatomy of the calcaneus so the subtalar joint and the calcaneocuboid joint remain in the proper relationship to each other is also necessary. These goals are vital for coordination of movement of the subtalar and midtarsal joints. The calcaneus can be thought of as having three poles: the tuber, the subtalar joint, and the anterior process (9). By placing these in exact relationship to each other, the subtalar and midtarsal joints will be in their original anatomic alignment and normal motion restored (12). "... [A] perfectly restored thalamus [posterior facet] embedded into the remaining parts of a complex fracture does not yield a good functional result" (26).

Finally, function will also be increased with early mobilization. It is well known that subtalar joint stiffness is a common postoperative complication of calcaneal fractures when the joint is immobilized for increased periods of time (14). Early return to motion is one of the goals set forth by the Association for the Study of Internal Fixation (AO/ASIF) and rigid internal fixation is the best means to that end (18, 27, 31, 32). Therefore,

to afford the patient the best possible chance to return to normal function, treatment with open reduction, internal fixation, and early return to motion is preferred over the other three methods (5, 7, 19, 26, 27, 32-36).

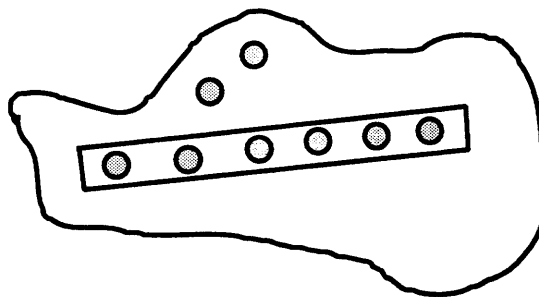
Contraindications to operative reduction include: nondisplaced fractures (Sanders' type I), patients with life-threatening injuries that preclude early intervention, severe peripheral vascular disease, and severe infirmity (25). In these instances, closed manipulation or traction with pins should be used. Primary arthrodesis should only be reserved for Sanders' type IV fractures, and anatomic reduction of the calcaneus must be performed concomitantly (25). Fracture blisters are a contraindication to immediate surgical intervention according to some authors (5, 9, 25), while others stress that an operating room is the best place to disrupt a blister and will allow earlier surgical intervention (2).

### Use of Plates

Plates have frequently been used to fixate calcaneal fracture reductions. Most plates are used with the greatest portion of them being placed on the lateral aspect of the calcaneus, so that it serves in neutralization and as a buttress of the lateral wall. The lateral surface is fairly flat and accepts a plate readily. Bending of the body of the plate will fix the heel in varus and should be avoided (31).

There are two basic types of plates: those with arms and those without arms. Plates without arms include one-third tubular plates, reconstruction plates (curved or straight), multiple fragment plates, cervical plates, or H-plates. Plates with arms include the Y-plate and the calcaneal reconstruction plate.

Plates without arms do not support the posterior facet when there is a defect in the body of the calcaneus underneath the posterior facet, but merely hold the anterior and posterior portions of the calcaneus in relation to each other. They are best suited for noncomminuted fractures. Separate screws are used to fixate the posterior subtalar joint (Fig. 3). In one study, 3 out of 47



**FIGURE 3** Plate on lateral aspect of the calcaneus with separate screws to fixate the posterior facet of the subtalar joint.

intra-articular fractures that used screws across the posterior facet and combination of screws and staples for the body suffered late collapse of the posterior facet (19). In another study, 1 out of 22 also had a late collapse (35).

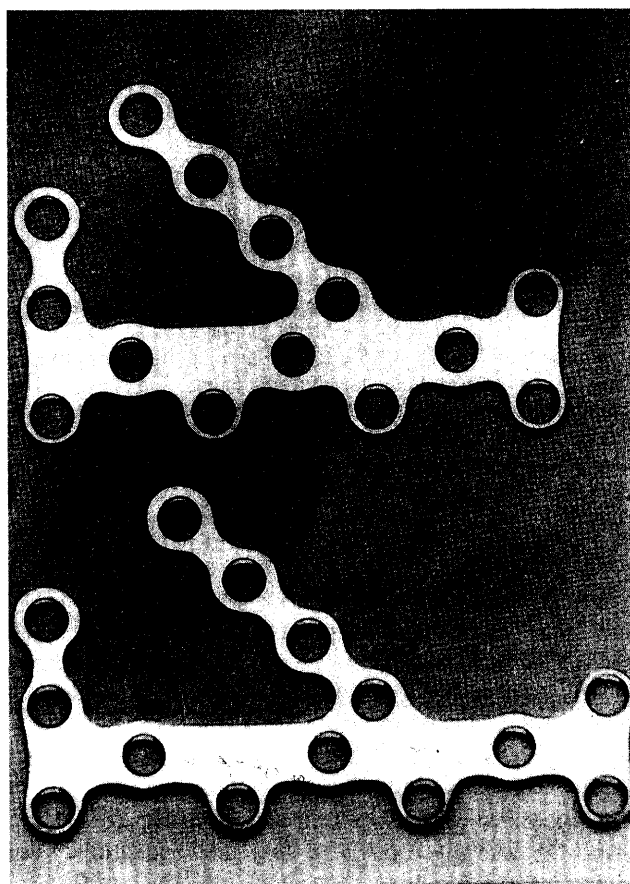
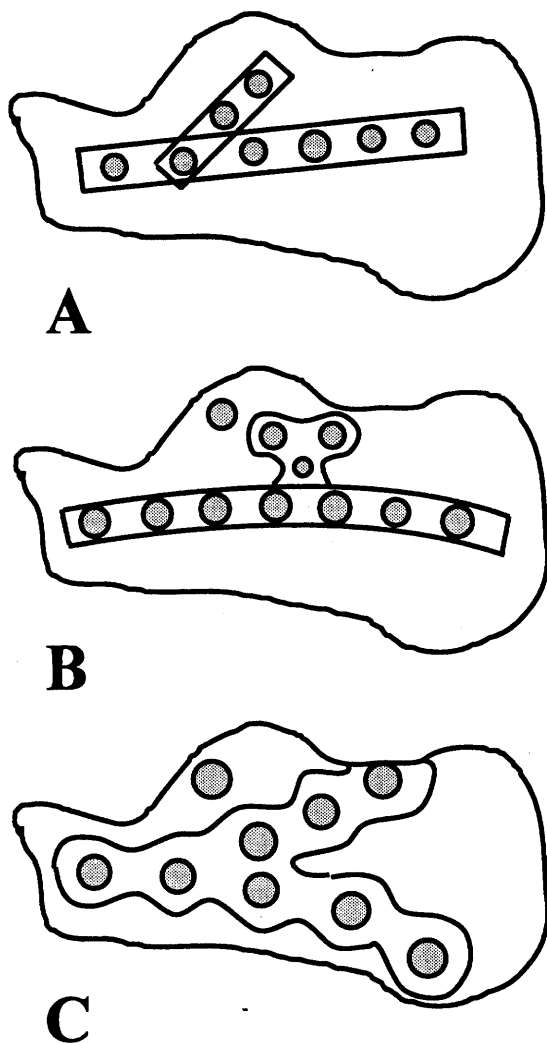
Screws from the plate are directed to the stable sustentaculum tali. When the plate has more holes, as with the multiple fragment, cervical or H-plates, more options for screw placement are available. Not all of the holes must be filled with screws.

Plates with arms have the added feature of supporting the posterior facet, which is advantageous in more comminuted fractures having a defect in the body of the calcaneus. Palmer used a bone graft wedged underneath the posterior facet, which served as the form of fixation (1). Various methods have been devised to support the posterior facet. Bezes *et al.* used a second short straight

plate forming a "Y-montage" (36) (Fig. 4A), which would appear to create an unnecessary bulge on the lateral side directly under the peroneal tendons. Another technique is to add a five-hole H-plate to the straight plate, but this would also produce an unnecessary bulge on the lateral aspect (Fig. 4B). A Y-plate (Fig. 4C) was advocated by Letournel because it runs parallel to the subtalar joint and the screws through the upper arm, "...reinforce the subtalar joint fixation" (9), although they are not the same screws fixating the posterior facet.

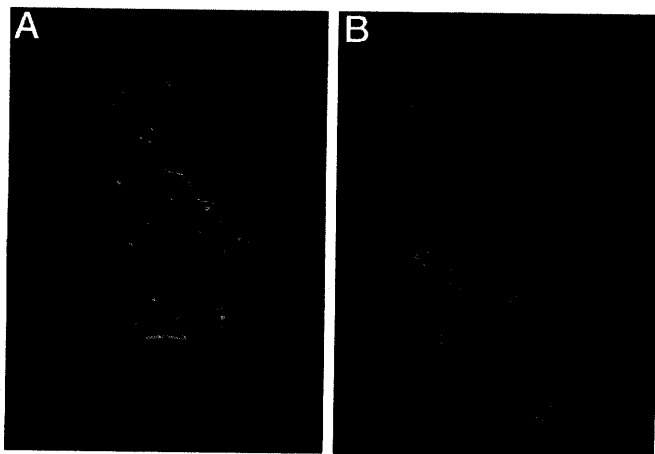
The calcaneal reconstruction plate (Fig. 5) combines the best aspects of all the plates. It consists of a 14-hole plate with a superior arm that more closely parallels the posterior aspect of the posterior facet. It is composed of stainless steel or titanium, is 1.2 mm. thick, and comes in 60-mm. or 70-mm. lengths.

The superior arm more closely parallels the subtalar joint and the screws holding the subchondral bone of the subtalar joint pass directly through the superior arm as opposed to the traditional Y-plate (Fig. 6A, B). This results in the posterior facet being directly supported by the plate or more accurately, the body being supported away from the posterior facet. The support is achieved

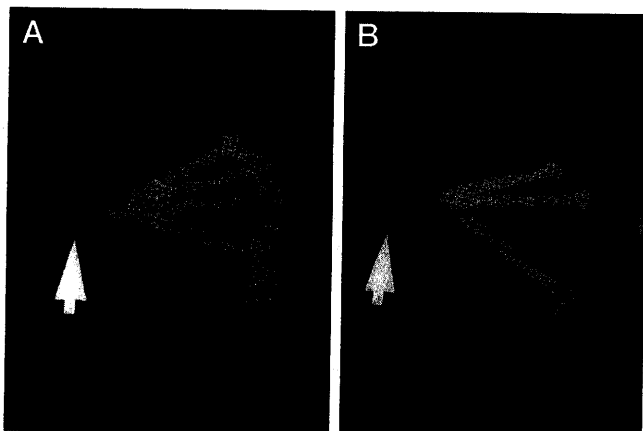

**FIGURE 4** Methods used to hold up the posterior facet when there is a cancellous defect of the body. A, Y-montage; B, 5-hole H-plate added to a curved reconstruction plate, C, Y-plate.

**FIGURE 5** Calcaneal reconstruction plate.



**FIGURE 6** A, Calcaneal reconstruction plate on lateral surface of bone model. Notice superior arm closely paralleling posterior facet. B, Dorsal surface of bone model. Notice screws from superior arm of the plate directed towards sustentaculum tali also fixates posterior facet. Type IIIAB fracture lines drawn on posterior facet.



**FIGURE 7** A, Anterior to posterior x-ray of bone model from Figure 6. Anterior and posterior screws from the body of the plate were removed for visualization. Arrow points to sustentaculum tali. Three superior screws course from superior arm of the plate into the sustentaculum and form the first arm of a triangle. The plantar screw is from the body of the plate into the sustentaculum and forms the second arm of a triangle. The laterally placed plate forms the third arm of a triangle. B, Bone model with fixation similar to Figure 3. A 1/3 tubular plate has been applied laterally with two screws fixating the posterior facet. No triangulation is achieved.

by triangulating the fixation as seen two-dimensionally in Figure 7. The triangulation occurs across the defect in the cancellous bone of the body of the calcaneus underneath the posterior facet. One arm of the triangle is a screw through the superior arm of the plate under the posterior facet directed to the sustentaculum, the second arm of a triangle is the screw from the body of the plate directed to the sustentaculum and the third arm of the triangle is the plate itself. The apex is the sustentaculum where the tips of the screws meet and the base is the plate. Since a triangle has only two dimensions, this may

be more accurately termed a four-sided pyramid, except for the fact that the base of the pyramid is the plate's "V" portion and not a triangle shape. Since the overall effect is one of serial triangulations radially centered around the sustentaculum tali, the term "triangulation" will be retained.

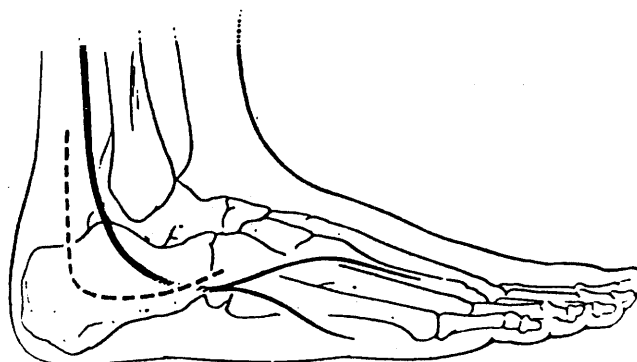
The patterns of holes in the main body of the calcaneal reconstruction plate provide for more screw placement options as comminution increases. This includes being able to fixate the anterior process when the calcaneo-cuboid joint is involved. An additional arm on the posterior aspect of the plate provides for more fixation into the tuber. This also makes it beneficial in tongue-type fractures, as two arms of the plate will cross the fracture line.

### Surgical Technique

"This is surgery in which the exactness of technique decides the outcome" (5). Surgery should be performed within 3 weeks, because early consolidation of the fracture may cause difficulties with reduction (7). The patient should be on complete bedrest with the limb elevated above the heart until the edema reduces enough to elicit a positive "wrinkle test," when the foot is dorsiflexed and everted (7). The patient is then taken to surgery and placed in the lateral decubitus position when a lateral approach is used.

There has been much debate in the literature concerning medial *versus* lateral incisions, but most recent authors prefer a lateral approach because their interest is in reducing the lateral aspect of the posterior subtalar joint. The medial sustentacular fragment is usually stable and the neurovascular structures are in close proximity. Most do agree, however, that a medial incision can be added in very severe cases (2, 7, 8, 14, 27, 37). An extended "L"-shaped incision is preferred when a lateral approach is used (2, 7, 14, 21, 27, 32, 37) (Fig. 8).

The incision initiates anterior to the Achilles tendon approximately 4 cm. above the calcaneus, proceeds to



**FIGURE 8** The extended "L" lateral incision and its relation to the sural nerve. (Used with permission).

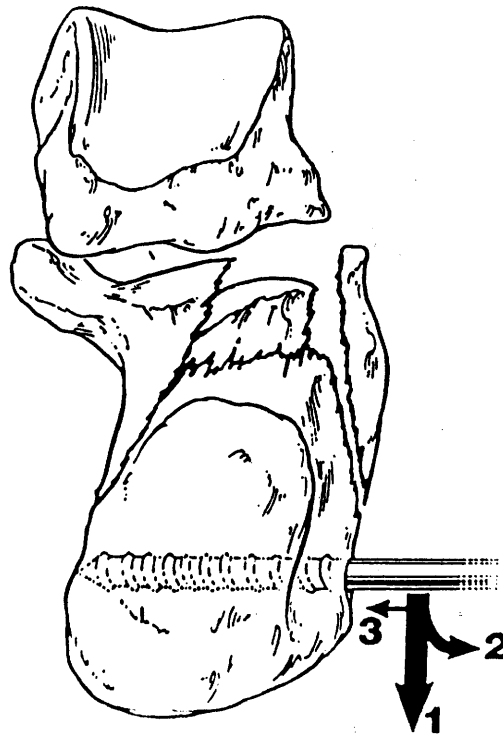
the junction of the lateral and plantar skin, and then courses anteriorly to the calcaneocuboid joint. Being careful of the sural nerve, the incision is deepened directly down to bone and dissection is carried out subperiosteally. The peroneal retinaculum and calcaneofibular ligament are transected. The flap is retracted anterolaterally and contains the sural nerve, peroneal tendons, and lesser saphenous vein. The fat plug from the sinus tarsi is removed and the extensor digitorum muscle is dissected anteriorly from its origin. This approach provides excellent exposure to the posterior facet, lateral wall, and anterior process. The flap is held in place with Kirschner wires driven into the talus and fibula, and is not touched after this point. Wound dehiscence is decreased postoperatively because of this atraumatic technique.

The fracture fragments are now identified and the clots are removed. One of two methods may now be employed. The first method advocated is reduction of the posterior facet initially and then reduction of the tuber (5, 9, 26, 27). The tuber may need to be mobilized first to reduce the posterior facet. The second method advocates reducing the tuber to the sustentaculum first, and then reducing the posterior facet. Benirschke accomplishes this by placing a large diameter (approximately 5 mm.) partially threaded K-wire into the tuber and then distracts the "fragment out to length, translated medially, and into slight valgus position" (31) (Fig. 9). Eastwood, Gregg, and Atkins accomplish this with an elevator placed across the fracture as a lever to pry the tuber plantar and posterior (11).

When using a calcaneal reconstruction plate, it is best to reduce the tuber first. The reduction can be examined with fluoroscopy. The posterior fragment is reduced by rotating it up into place. This can be accomplished by prying the fragment up. The lateral wall fragment may have to be taken out as a cortical window to allow reduction of the centrally depressed fragment (Fig. 9).

Once the posterior facet is in position, a Kirschner-wire is used for fixation. A second K-wire is placed using the calcaneal reconstruction plate as a guide for spacing. The superior arm is next bent to match the contours of the posterior facet. Congruity of the posterior facet is evaluated under fluoroscopy by scanning the joint with Broden's views. If the posterior facet is satisfactorily reduced, screws replace the K-wires. Cannulated screws are well suited for this application, but a standard set may be employed by placing a screw into the third hole of the superior arm, and then replacing the K-wires with screws individually. Hence, there are always two points of fixation to prevent the fragments from rotating, which would result in incongruity of the joint.

The posterior aspect is secured next and then attention is directed to reducing the calcaneocuboid joint.



**FIGURE 9** Means of reducing the tuber out to its original length. In reducing the posterior facet, the lateral cortical wall may be removed as a cortical window, so the lateral portion of the posterior facet can be reduced under direct visualization. (Used with permission).

The anterior and posterior portions of the calcaneus can be aligned using the cortical struts of the crucial angle (2). Additional screws are placed through the midsection of the plate directed toward the stable sustentaculum fragment. The fixation, unless the calcaneus is severely comminuted, should be stable enough for subtalar joint motion to be evaluated (26).

The initial injury results in compression of the posterior facet into the cancellous bone of the body and results in a defect. Palmer originally inserted a bone graft to maintain the posterior facet in place (1). Today with internal fixation, the defect may or may not be filled with bone graft. Some authors feel it is necessary, either because it improves osteoconduction or osteoinduction, or it holds up the posterior facet fragment (2, 5, 31-33, 37). Other authors have shown the defect fills in by itself and does not need to be grafted (6, 19, 21, 24-26, 38). Obviously, this remains a surgeon's preference.


A closed suction drain is usually placed, the K-wires are removed, the soft-tissue flap is reapproximated with absorbable sutures, and the skin is closed with staples and sealed with Betadine ointment. A bulky compressive dressing is applied and a posterior splint is added. Postoperatively, the patients must be non-weightbearing for a minimum of 2 to 3 months. Immobilization is

recommended from 3 days to several weeks to allow the flap to heal. Range of motion exercises should be instituted as soon as possible. The patient can bear partial weight at 2 to 3 months and full weightbearing will depend on radiographic healing.

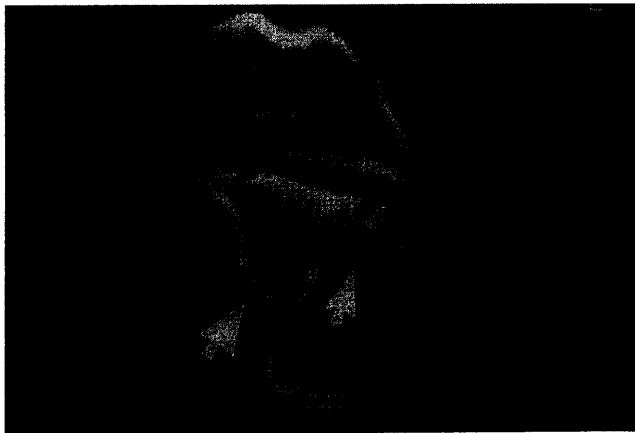
### Case Report

A 56-year-old female presented to the emergency room after falling off the sixth rung of a ladder. The patient related no pains other than her left heel. Neurovascular status was intact and there were no fracture blisters. Past medical history was unremarkable. Plain films revealed a joint-depression fracture (Fig. 10). CT films revealed a Sanders' type IIIAB fracture of the posterior facet (Fig. 11). The lateral wall and calcaneocuboid joint were comminuted (Fig. 12). The calcaneal tuber was noted to be intact.

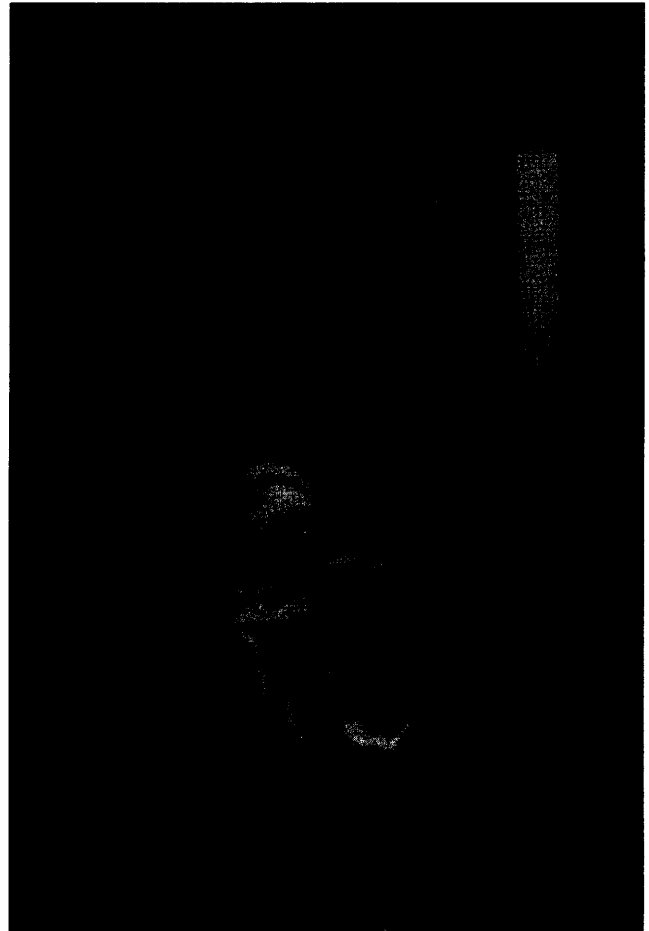
Based on these findings, open reduction with internal



**FIGURE 10** Initial lateral plain film revealed joint depression fracture of left calcaneus.



**FIGURE 11** Coronal CT scan. It is a Sanders' type IIIAB intra-articular calcaneal fracture. Fracture lines are indicated by the two arrows. Depression and rotation of the lateral portion of the posterior facet (marked with a diamond) is seen.




**FIGURE 12** Coronal CT scan. Evident is the fractured anterior process of the body of the calcaneus near the calcaneocuboid joint and the intact talar neck. Refer to Fig. 1D for a transverse section of the calcaneus.

fixation was chosen to treat the fractures. Due to the comminution of the lateral wall, the position of the lateral aspect of the posterior facet, and comminution of the calcaneocuboid joint, the use of a calcaneal reconstruction plate was planned. This would allow better reconstruction of the anatomy, and an earlier return of motion would result from more stable fixation afforded by this plate.


The risks and benefits were explained to the patient. It was stressed that the main goal was to restore the height and width of the calcaneus so it could appropriately support the body's weight and normal shoe gear could be worn. Secondly, the joints would be reapproximated so that a better return to function might be achieved. The patient was informed that additional surgery would be needed if the joints developed painful arthritis, if the metal hardware became intolerable, or because of an infection. The patient agreed to an open reduction with internal fixation of her calcaneus. She was placed on bedrest until the edema decreased sufficiently.

## Operative Technique

The patient was taken to surgery on the ninth day after injury and placed under general anesthesia, in the lateral decubitus position. For antibiotic prophylaxis, 1 gm. of cefazolin IV push was given preoperatively. An extended "L"-shaped lateral incision was used (Fig. 13). A portion of the lateral wall containing the peroneal tubercle was free and removed as a cortical window and placed in saline. There was also a fracture through the crucial angle, a dorsolateral fragment that extended from the crucial angle to the calcaneocuboid joint. A large-diameter (approximately 5 mm.) K-wire was placed transversely through the intact tuber. The tuber was mobilized and then reduced. The reduction was checked by fluoroscopy. The posterior facet was reduced by rotating the lateral fragment into place and prying up the middle fragment (Fig. 14). Two K-wires were then placed into the subchondral bone directed into the sustentaculum tali as described earlier. This was evaluated under fluoroscopy using multiple Broden's views.



**FIGURE 13** Intra-operative. Note extended "L" incision. Forceps is pointing to where the lateral wall of the posterior facet should be. Underside of the talus is barely visible in this photograph.

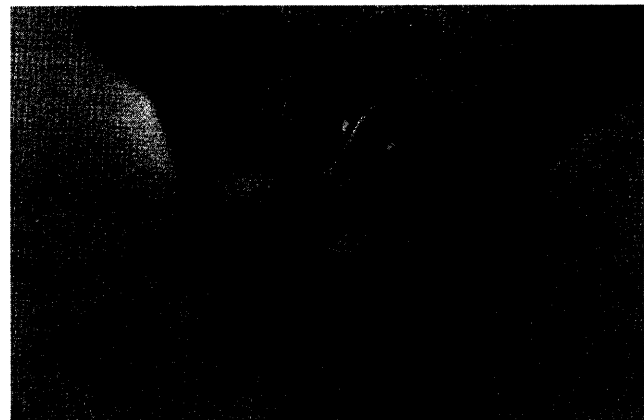


**FIGURE 14** Posterior facet is reduced. First K-wire in place. Notice pin in the tuber of the calcaneus.


The calcaneal reconstruction plate's superior arms were pre-bent and checked by placing it over the K-wires. The screws for the posterior facet were placed into the superior arm of the plate. Then screws were placed into the posterior aspect of the plate. Some were directed into the tuber and the more anterior screws were directed into the sustentaculum (Fig. 15).

The lateral cortical window was placed back onto the calcaneus under the plate and reduction of the anterior process was performed. It was reduced, held with a bone clamp, and final screws were placed into the anterior aspect of the plate. The resultant defect in the body of the calcaneus was not filled with a bone graft. A total of nine 4.0-mm. cannulated screws were used (Fig. 16). A closed suction drain was placed, the K-wires used for retraction were removed, and the flap was reapproximated with absorbable sutures. The skin was closed with staples. A sterile compression dressing and posterior splint were applied.

The patient was immobilized for 3 weeks to allow the incision to heal. No skin slough or wound edge necrosis



**FIGURE 15** Intra-operative view with plate in place and screws placed into the posterior facet.



**FIGURE 16** Postoperative lateral x-ray. Note triangulation of fixation and defect in the body of the calcaneus.


was found. Active range of motion was instituted. Physical therapy consisting of active and passive exercises to increase range of motion was added at 6 weeks. By 9 weeks, adequate consolidation was seen on x-rays and the patient was allowed to ambulate with partial weight-bearing in a removable walking cast. At 12 weeks, a surgical shoe was dispensed, and at 14 weeks the patient was allowed to wear high-top athletic shoes. Range of motion at this time was rated at 60% of normal.

After prolonged ambulation, the patient complained of pain laterally and peroneal tendonitis was diagnosed. The internal fixation devices were removed at 6 months (Fig. 17). The same incision was used. It was noted that a screw had backed out approximately 1 mm. directly under the peroneal tendons. Inspection of the joint space was difficult at this time. The pain from the peroneal tendonitis disappeared, but the patient began complaining of subtalar joint pain. CT scans were obtained. A "near-anatomic" reduction according to Sanders *et al.* was seen. Joint space narrowing was evident at the lateral aspect of the posterior subtalar joint (Fig. 18). Otherwise the height, width, and length had been restored and maintained near-normal (Fig. 19).

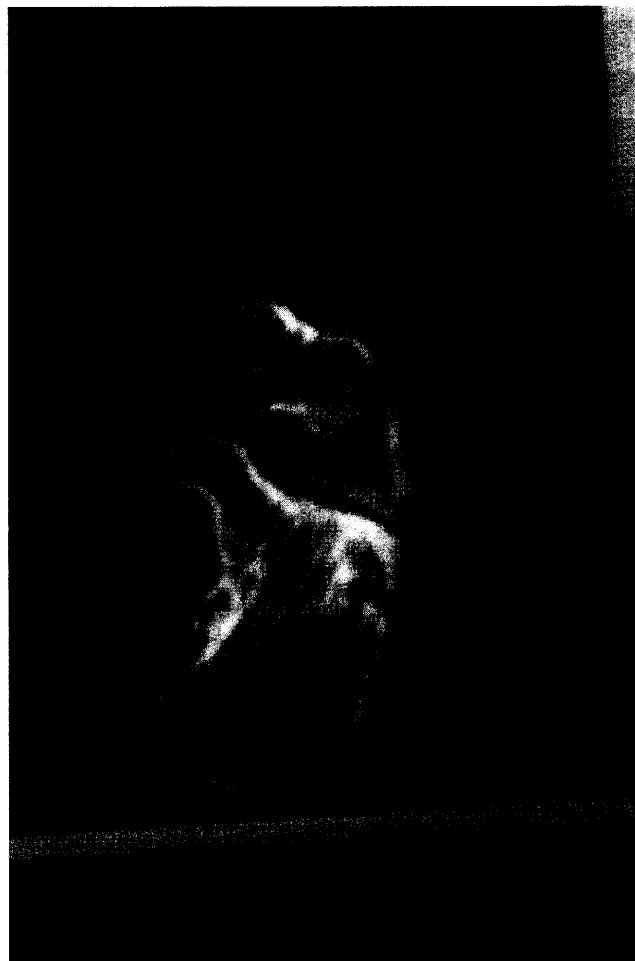The patient complains of mild subtalar joint arthritis and was casted for orthotics to control subtalar joint movement. The patient is now 18 months postoperative and continues to walk further without pain and participate in most of her daily activities. She does report that occasionally she will take over-the-counter anti-inflammatory medication after prolonged standing because of stiffness in her subtalar joint. X-rays at 18 months can be seen in Figure 20.

### Conclusion

Intra-articular calcaneal fractures have always had a poor prognosis. Technology and technique have overcome most of the obstacles to obtaining a good clinical



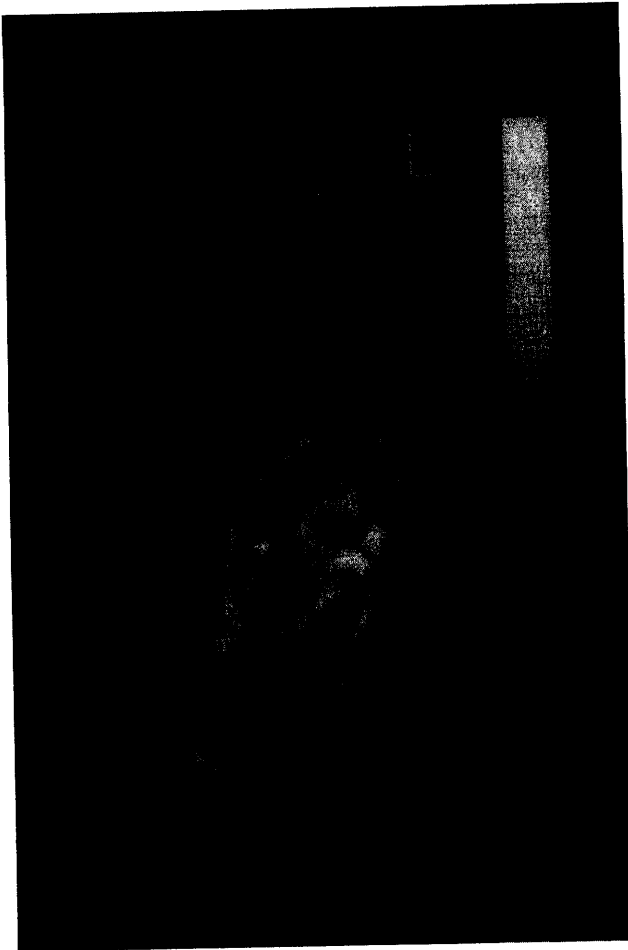
**FIGURE 17** Postoperative plate removal at 6 months.



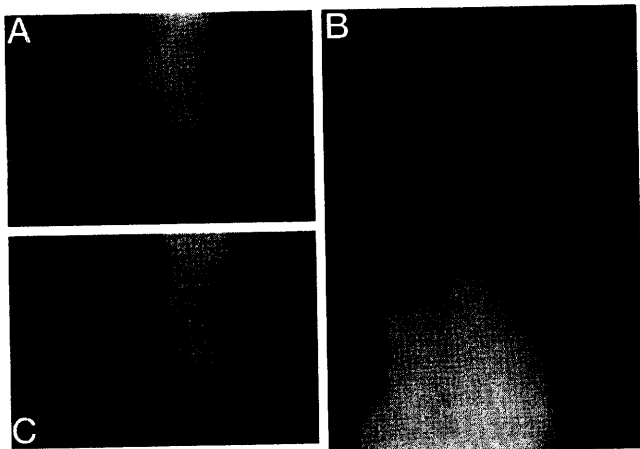
**FIGURE 18** Coronal plane CT at 9 months postoperative. Compare to Figure 11. Reduction is "near-anatomic."

result. While an "... anatomic articular reduction is necessary for a good outcome, it cannot guarantee it..." (7). There may be cartilage damage from the original injury that will lead to arthritis (4, 7). In the study by Sanders *et al.*, 14 "anatomic" reductions of type II and III fractures required a subtalar fusion. Inspection of the joint at the time of subtalar fusion showed damaged cartilage with an anatomically reduced articular surface. Overall, subtalar fusions were needed in 8% of type II fractures and 23% of type III fractures (7).

As calcaneal fractures become more comminuted, the prognosis worsens. Anatomic reduction of the deformity with internal fixation and early range of motion provide for the best possible chance for the patient to return to near-normal pre-injury function. Various plates have been employed toward this goal. The calcaneal reconstruction plate aided in reduction of a type IIIAB fracture by providing triangulation of fixation and a more stable result, and the authors feel it may also aid in similar types of fractures.



**FIGURE 19** Transverse plane CT at 9 months postoperative. Compare to Figure 1D.



**FIGURE 20** A, Lateral x-ray at 18 months postoperative. B, Dorsal-plantar projection x-ray at 18 months postoperative. C, Lateral oblique projection x-ray at 18 months postoperative.

## References

- Palmer, I. The mechanism and treatment of fractures of the calcaneus. *J. Bone Joint Surg.* 30A:2-8, 1948.
- Schuberth, J. M., Karlin, J. M., Daly, N. Fractures of the calcaneus, ch. 24. In *Trauma of the Foot and Ankle*, pp.439-471, edited by B. Scurran, Churchill Livingstone, Inc., New York, 1989.
- Warrick, C. K., Bremner, A. E. Fractures of the calcaneum: with an atlas illustrating the various types of fracture. *J. Bone Joint Surg.* 35-B:33-45, 1953.
- Burdeaux, B. D. Reduction of calcaneal fractures by the McReynolds medial approach technique and its experimental basis. *Clin. Orthop.* 177:87-103, 1993.
- Ruch, J. A., Taylor, G. C. Calcaneal Fractures, ch. 64. In *Comprehensive Textbook of Foot Surgery*, 2nd ed., vol. 2, pp. 1543-1573, edited by E. D. McGlamry, A. Banks, and M. Downey. Williams & Wilkins, Baltimore, 1993.
- Essex-Lopresti, P. The mechanism, reduction, technique, and results in fractures of the os calcis. *Br. J. Surg.* 39:395-419, 1952.
- Sanders, R. Intra-articular fractures of the calcaneus: present state of the art. *J. Orthop. Trauma* 6:252-265, 1992.
- Gilmer, P. W., Herzenberg, J., Frank, J. L., Silverman, P., Martinez, S., Goldner, J. L. Computerized tomographic analysis of acute calcaneal fractures. *Foot Ankle* 6:184-193, 1986.
- Letournel, E. Open reduction and internal fixation of calcaneus fractures, ch. 14. In *Techniques in Orthopedics; Topics in Orthopedic Trauma*, pp. 173-192, edited by P. G. Spiegel, University Park Press, Baltimore, 1984.
- Romash, M. M. Calcaneal fractures: three-dimensional treatment. *Foot Ankle* 8:180-197, 1988.
- Eastwood, D. M., Gregg, P. J., Atkins, R. M. Intra-articular fractures of the calcaneum; Part I: pathological anatomy and classification. *J. Bone Joint Surg.* 75B:176-188, 1993.
- Carr, J. B., Hamilton, J. J., Bear, L. S. Experimental intra-articular calcaneal fractures: anatomic basis for a new classification. *Foot Ankle* 10:81-87, 1989.
- Paley, D., Hall, H. Calcaneal fracture controversies: can we put Humpty Dumpty together again? *Orthop. Clin. North Am.* 20:665-77, 1989.
- Giachino, A. A., Uhthoff, H. K. Current concepts review: intra-articular fractures of the calcaneus. *J. Bone Joint Surg.* 71-A:784-786, 1989.
- Herzenberg, J. E. CT of calcaneal fractures (letter). *Am. J. Radiol.* 146:644-645, 1986.
- Lowrie, I. G., Finlay, D. B., Brenkel, I. J., Gregg, P. J. Computerized tomographic assessment of the subtalar joint in calcaneal fractures. *J. Bone Joint Surg.* 70-B:247-50, 1988.
- Bohler, L. Diagnosis, pathology, and treatment of fractures of the os calcis. *J. Bone Joint Surg.* 13:75-89, 1931.
- Stephenson, J. R. Displaced fractures of the os calcis involving the subtalar joint: the key role of the superomedial fragment. *Foot Ankle* 4:91-101, 1983.
- Hutchinson, F., Huebner, M. K. Treatment of os calcis fractures by open reduction and internal fixation. *Foot Ankle* 15:225-232, 1994.
- Koval, K. J., Sanders, R. The radiologic evaluation of calcaneal fractures. *Clin. Orthop.* 290:41-46, 1993.
- Sanders, R., Hansen, S. T., McReynolds, I. S. Fractures of the calcaneus, ch 84. In *Disorders of the Foot and Ankle*, 2nd ed., pp. 2326-2354, edited by M. Jahss, W. B. Saunders Co., Philadelphia, 1993.
- Janzen, D. L., Connell, D. G., Munk, P. L., Buckley, R. E., Meek, R. N., Schechter, M. T. Intraarticular fractures of the calcaneus: value of CT findings in determining prognosis. *Am. J. Roentgenol.* 158:1271-1274, 1992.
- Rowe, C. R., Sakellarides, H. T., Freeman, P. A., Sorbie, C. Fractures of the os calcis: a long term follow-up study of 146 patients. *J.A.M.A.* 184:920-923, 1963.

24. Soeur, R., Remy, R. Fractures of the calcaneus with displacement of the thalamic portion. *J. Bone Joint Surg.* 57B:413-421, 1975.
25. Sanders, R., Fortin, P., DiPasquale, T., Walling, A. Operative treatment in 120 displaced intraarticular calcaneal fractures: results using a prognostic computed tomography scan classification. *Clin. Orthop.* 290:87-95, 1993.
26. Letournel, E. Open treatment of acute calcaneal fractures. *Clin. Orthop.* 290:60-67, 1993.
27. Johnson, E. E., Gebhardt, J. S. Surgical management of calcaneal fractures using bilateral incisions and minimal internal fixation. *Clin. Orthop.* 290:117-124, 1993.
28. Kenwright, J. Fractures of the calcaneum (editorial). *J. Bone Joint Surg.* 75B:176-177, 1993.
29. Melcher, G., Bereiter, H., Leutenegger, A., Ruedi, T. Results of operative treatment for intra-articular fractures of the calcaneus. *J. Trauma* 31:234-38, 1991.
30. Hammesfahr, J. F. Surgical treatment of calcaneal fractures. *Orthop. Clin. North Am.* 20:679-689, 1989.
31. Benirschke, S. K., Sangeorzan, B. J. Extensive intraarticular fractures of the foot: surgical management of calcaneal fractures. *Clin. Orthop.* 292:128-134, 1993.
32. Leung, K. S., Yuen, K. M., Chan, W. S. Operative treatment of displaced intra-articular fractures of the calcaneum. *J. Bone Joint Surg.* 75B:196-201, 1993.
33. Leung, K. S., Chan, W. S., Shen, W. Y., Pak, P. P. L., So, W. S., Leung, P. C. Operative treatment of intraarticular fractures of the os calcis—the role of rigid internal fixation and primary bone grafting: preliminary results. *J. Orthop. Trauma* 3:232-240, 1989.
34. Zwipp, H., Tscherne, H., Thermann, H., Weber, T. Osteosynthesis of displaced intraarticular fractures of the calcaneus: results in 123 cases. *Clin. Orthop.* 290:76-86, 1993.
35. Stephenson, J. R. Treatment of displaced intra-articular fractures of the calcaneus using medial and lateral approaches, internal fixation, and early motion. *J. Bone Joint Surg.* 69A:115-130, 1987.
36. Bezes, H., Massart, P., Delvaux, D., Fourquet, J. P., Tazi, F. The operative treatment of intraarticular calcaneal fractures: indications, technique, and results in 257 cases. *Clin. Orthop.* 290:55-59, 1993.
37. Fernandez, D. L., Koella, C. Combined percutaneous and "minimal" internal fixation for displaced articular fractures of the calcaneus. *Clin. Orthop.* 290:108-116, 1993.
38. Eastwood, D. M., Langkamer, V. G., Atkins, R. M. Intra-articular fractures of the calcaneum. *J. Bone Joint Surg.* 75-B:189-195, 1993.

### Additional References

- Noble, J., McQuillan, W. M. Early posterior subtalar fusion in the treatment of fractures of the os calcis. *J. Bone Joint Surg.* 61B:90-93, 1979.
- Paley, D., Fischgrund, J. Open reduction and circular external fixation of intraarticular calcaneal fractures. *Clin. Orthop.* 290:125-31, 1993.
- Stephenson, J. R. Surgical treatment of displaced intraarticular fractures of the calcaneus: a combined medial and lateral approach. *Clin. Orthop.* 290:68-75, 1993.
- Albert, M. J., Waggoner, S. M., Smith, J. W. Internal fixation of calcaneus fractures: an anatomical study of structures at risk. *J. Orthop. Trauma* 9:107-112, 1995.